



Placement of 10 monobloc zirconia implants

Z-Systems Z3 ball implant overdenture system

85 yr old female presented in 2011 with history of ill fitting complete upper denture and lower partial denture. #31 was severely decayed and non restorable.

#31 was surgically removed, and complete dentures were fabricated. Z3 4x11 lockball implants were placed in areas ##2,6,8,11,14,22,24,25,27. Dentures were blocked out to prevent micro movement.

After 3 months, o-ring housings were added to the dentures. Bite was balanced, as necessary.

The patient's main complaint now is that she is gaining weight because she can eat whatever she wants!

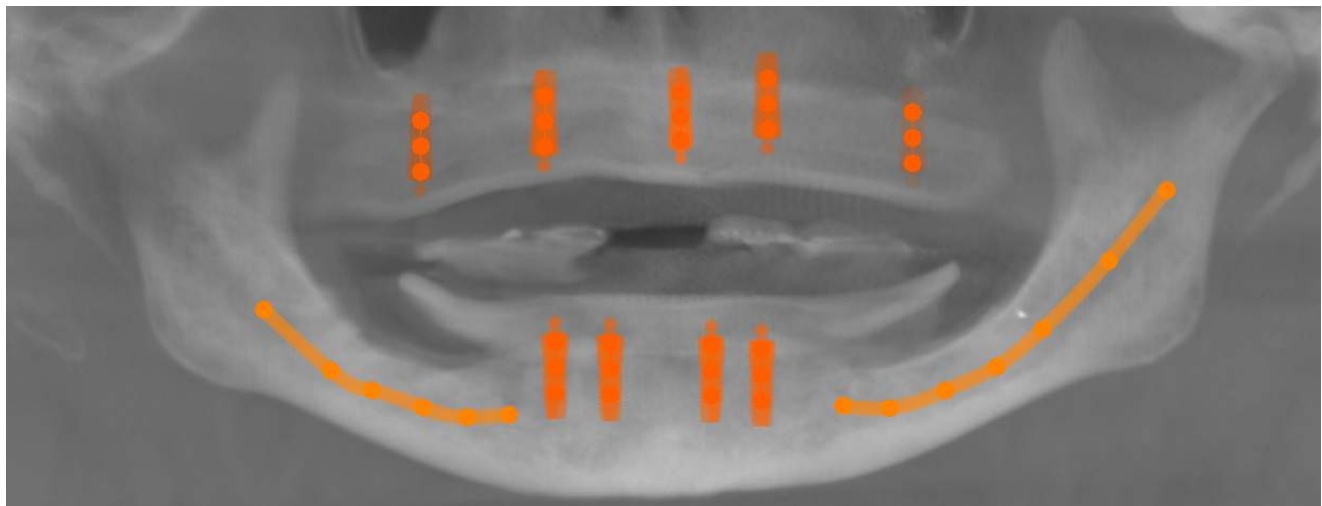


Fig. 1: Carestream 9500 cbct showing proposed zirconia implant placement

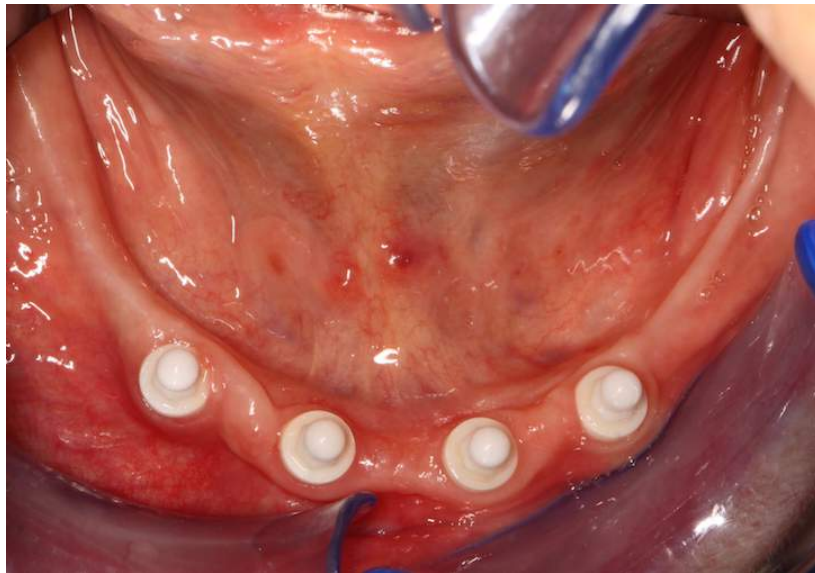
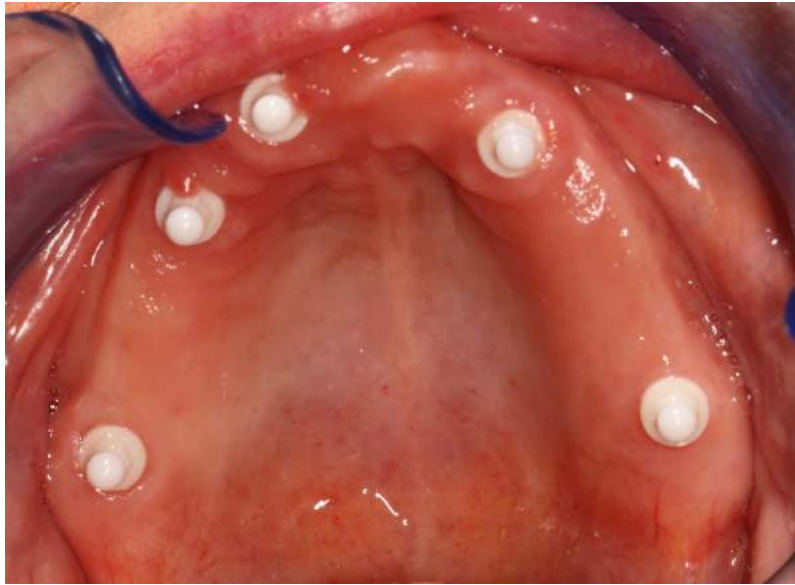


Fig. 2: Z3 lockball implants in situ

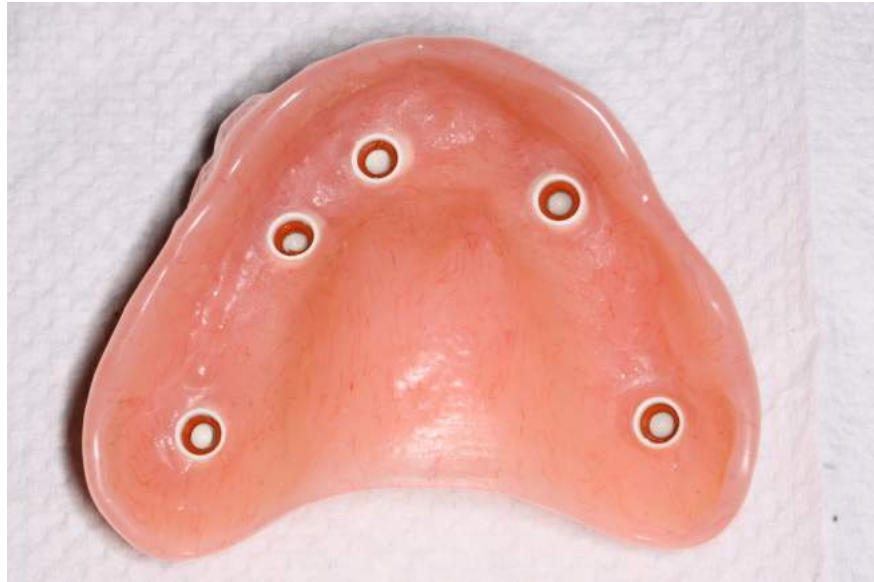

Fig. 3: tissue side of upper complete implant supported denture

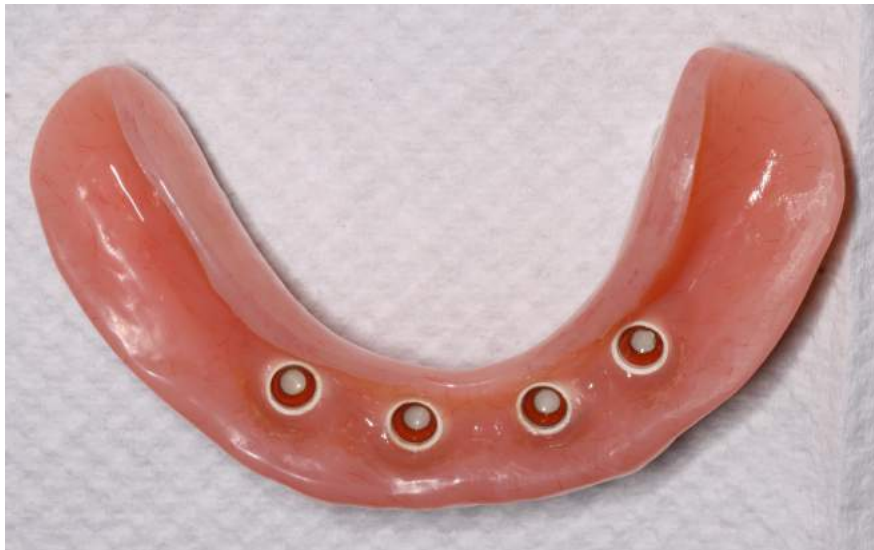

Fig. 4: tissue side of lower complete implant supported denture



Fig. 5: happy patient