



## Placement of 1 monobloc zirconia implant

Z-Systems z5m implant system

34 yr old female presented in 2014 with history of recurrent joint infections, increased ASO antibodies, chronic low grade fever, and poor digestion. Orofacial and radiographic examination revealed failed root canal treated tooth #6 with mild periapical bone loss and a 15mm spherical area of decreased bone density where #1 used to reside. Multiple dissimilar metals, including mercury were also present.

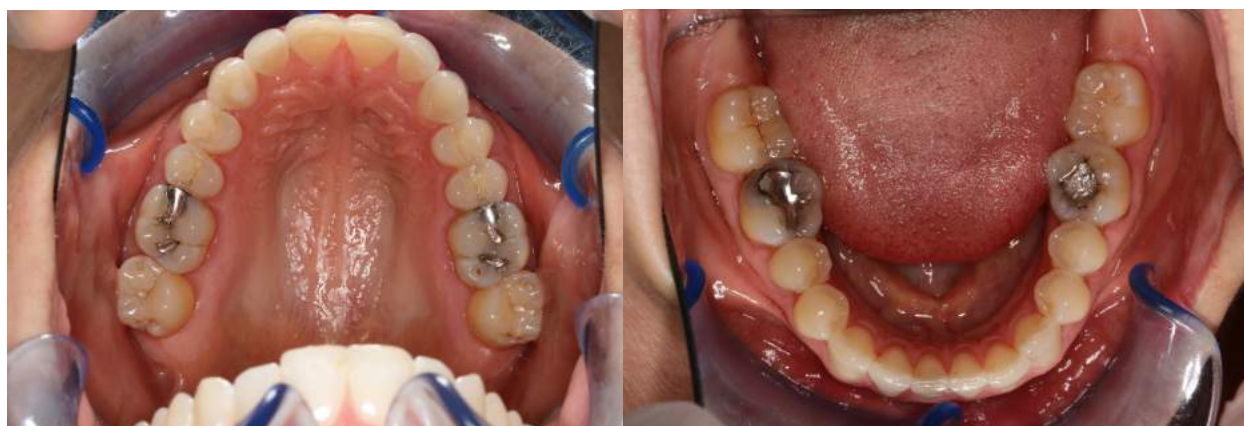
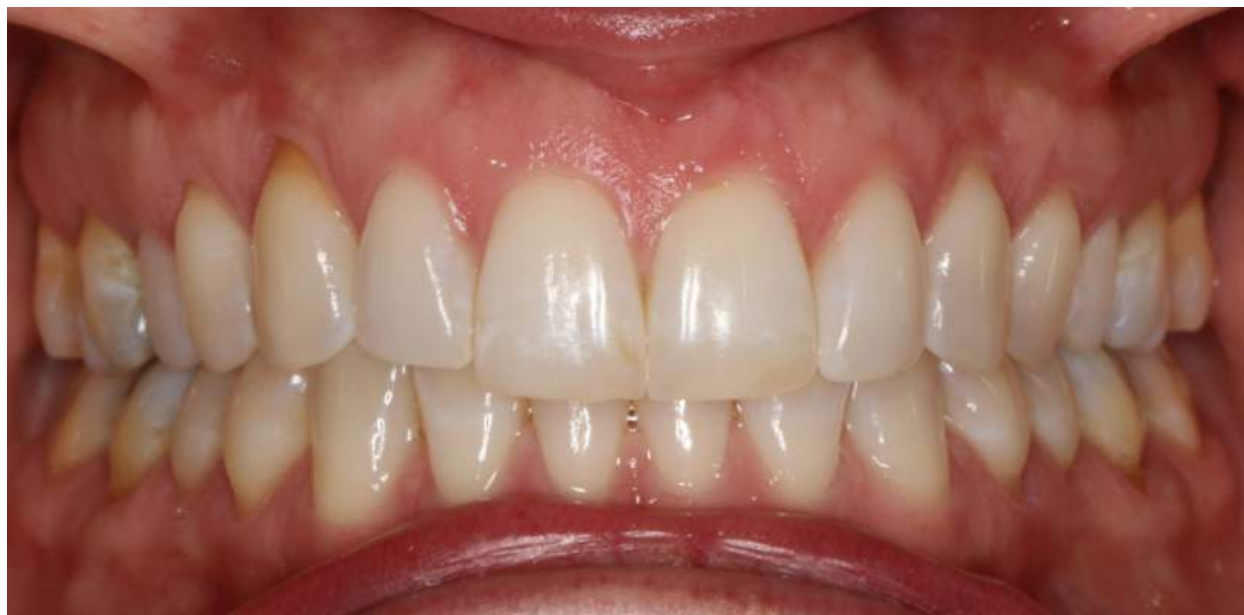
Fig. 1: Pretreatment photographs

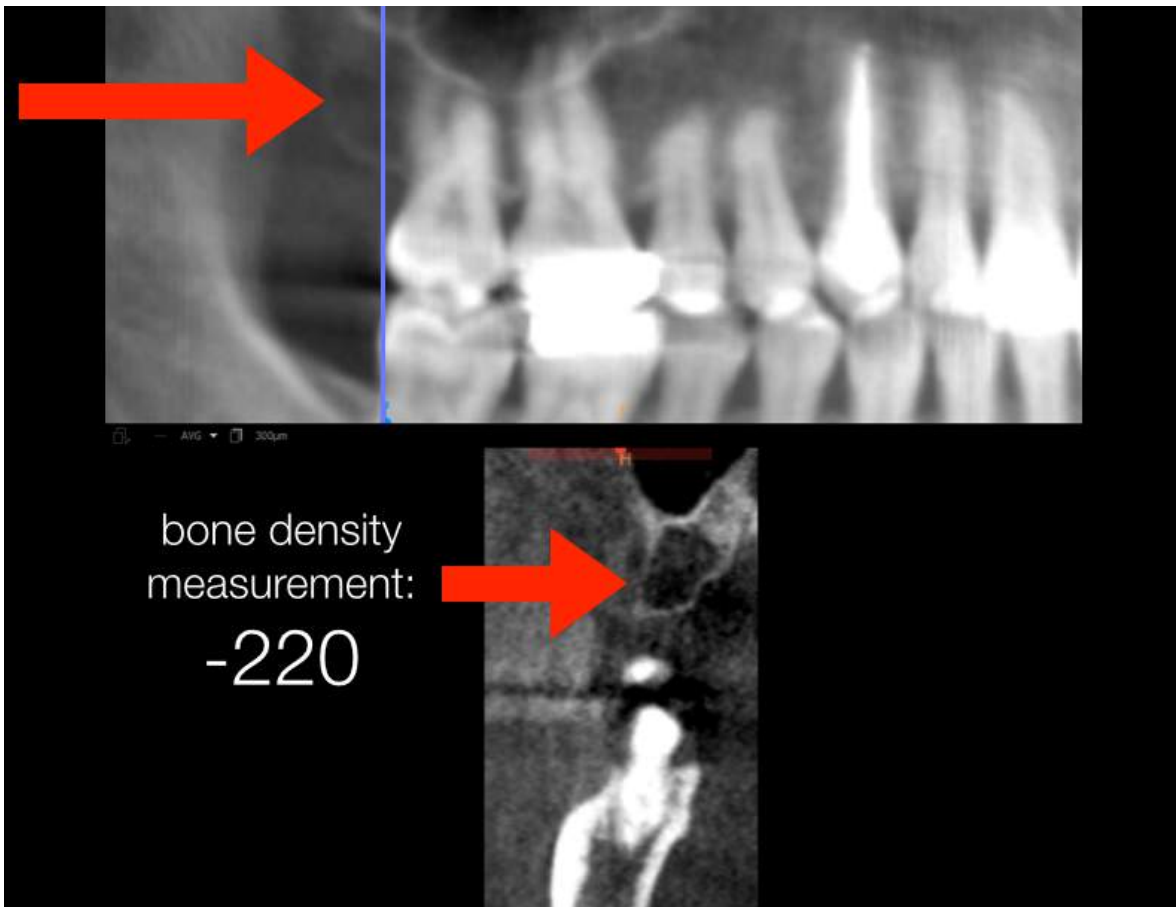
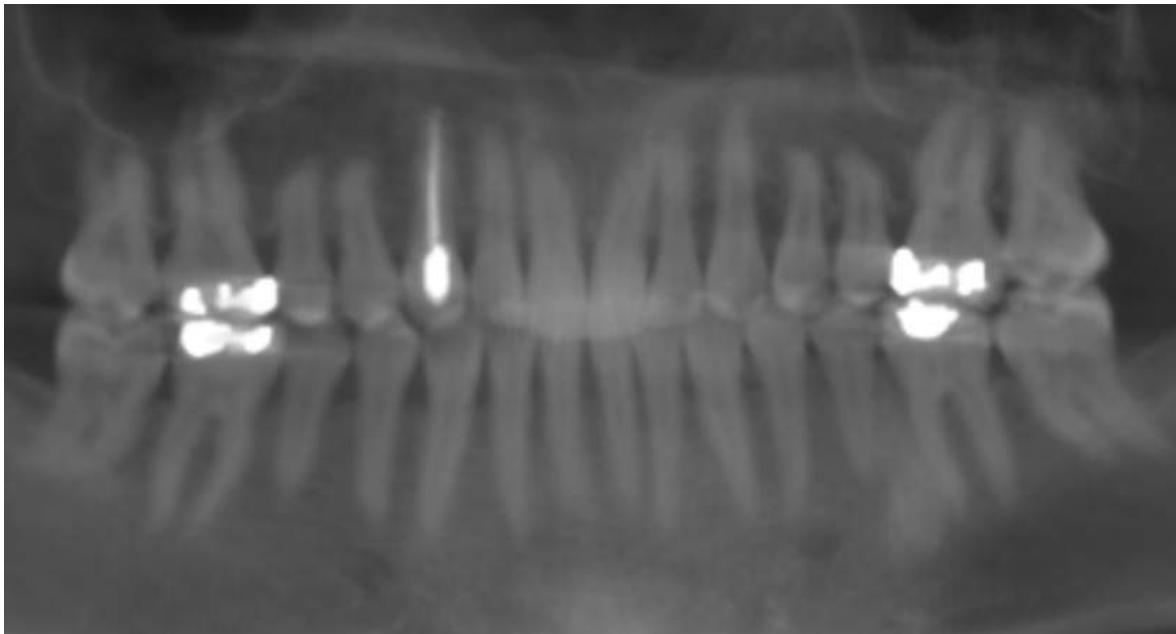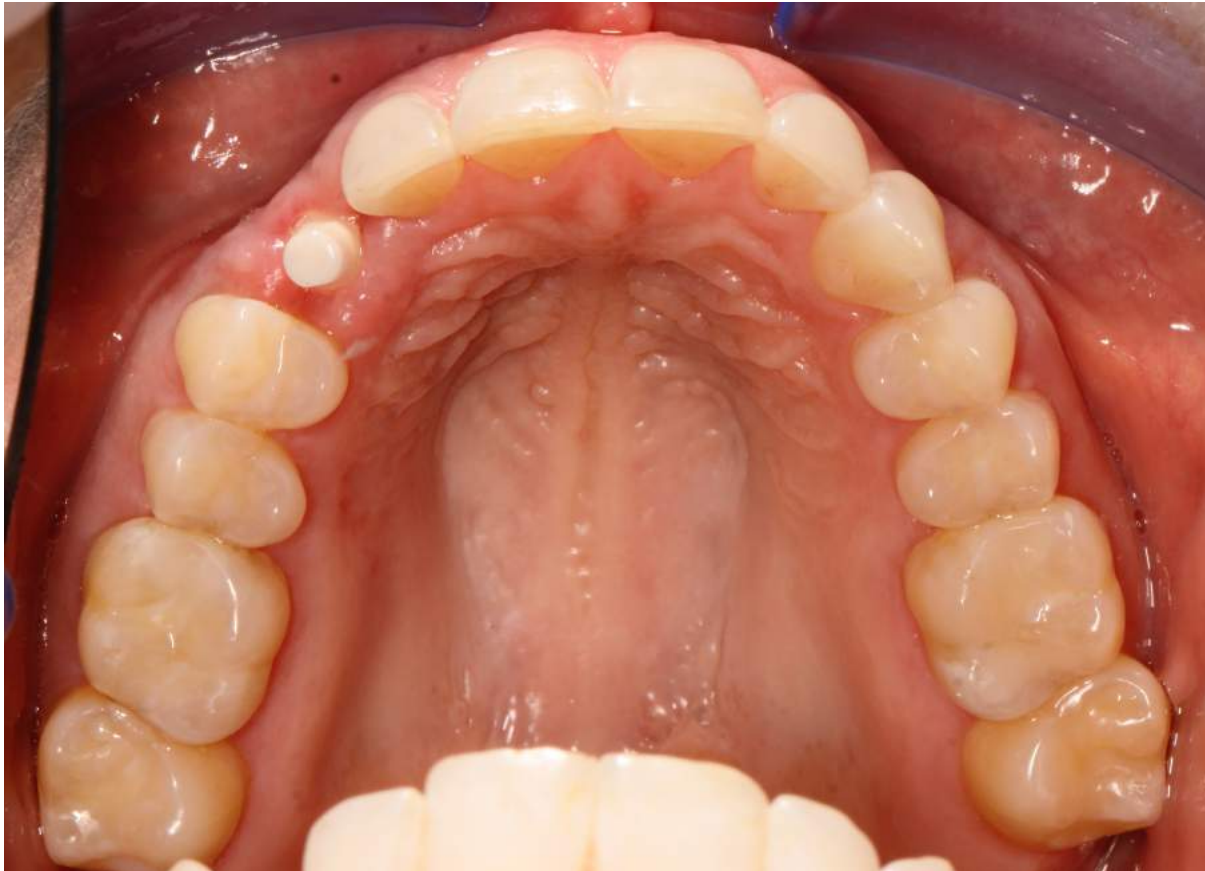


Fig. 2: Pretreatment radiographs from Kodak 9500 cbct

#6 was surgically removed, being careful to remove all diseased tissue and PDL fibers with ultrasonic piezotome and ozonated saline. PRF was used to graft the extraction site. #1 area was also biopsied, surgically debrided, flushed with ozonated saline, fumigated with ozone gas, sanitized with the Er:YAG laser, and grafted with PRF. All metals were safely removed and replaced with bonded restorations.



*Fig. 3: 1 week post operative photograph*

A flexible base RPD was fabricated for esthetic and functional purposes.

After 5 months of healing, a cone beam scan was made to assess bone quantity and quality.

In order to obtain more ridge width, a ridge split was performed prior to placing a 4x10 z5m implant. The implant was protected and temporized with a clear 1.0 essix with an esthetic composite shell.

After 4 months of integration, Periotest measurements confirmed readiness to restore.

#6 implant was scanned with the Trios system. The scan was milled in-house with the AmannGirbacch Ceramill 2 cad/cam system. Patient reports significant decrease in joint pain and improved digestion.

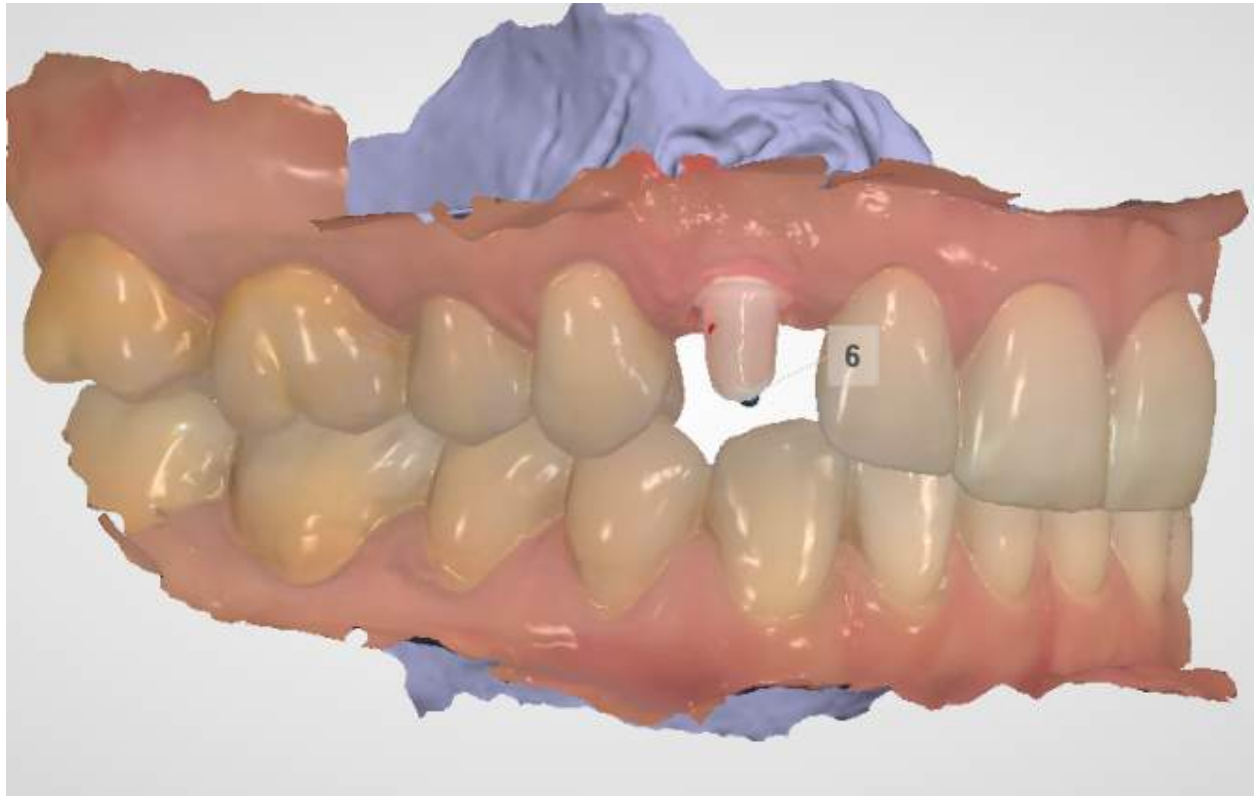
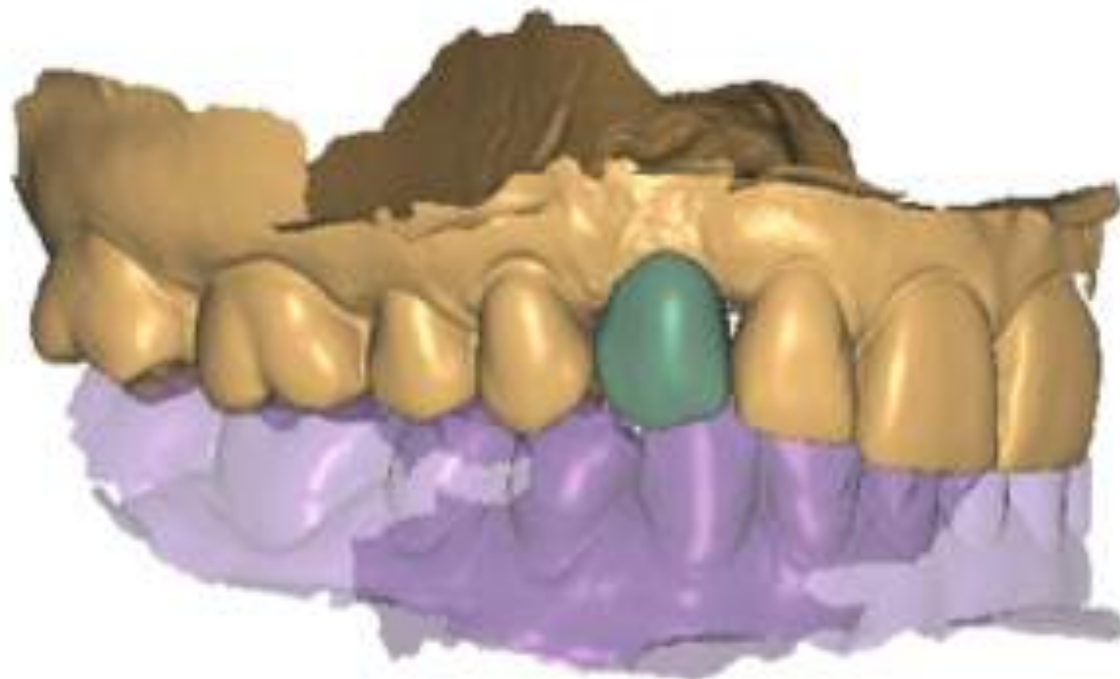
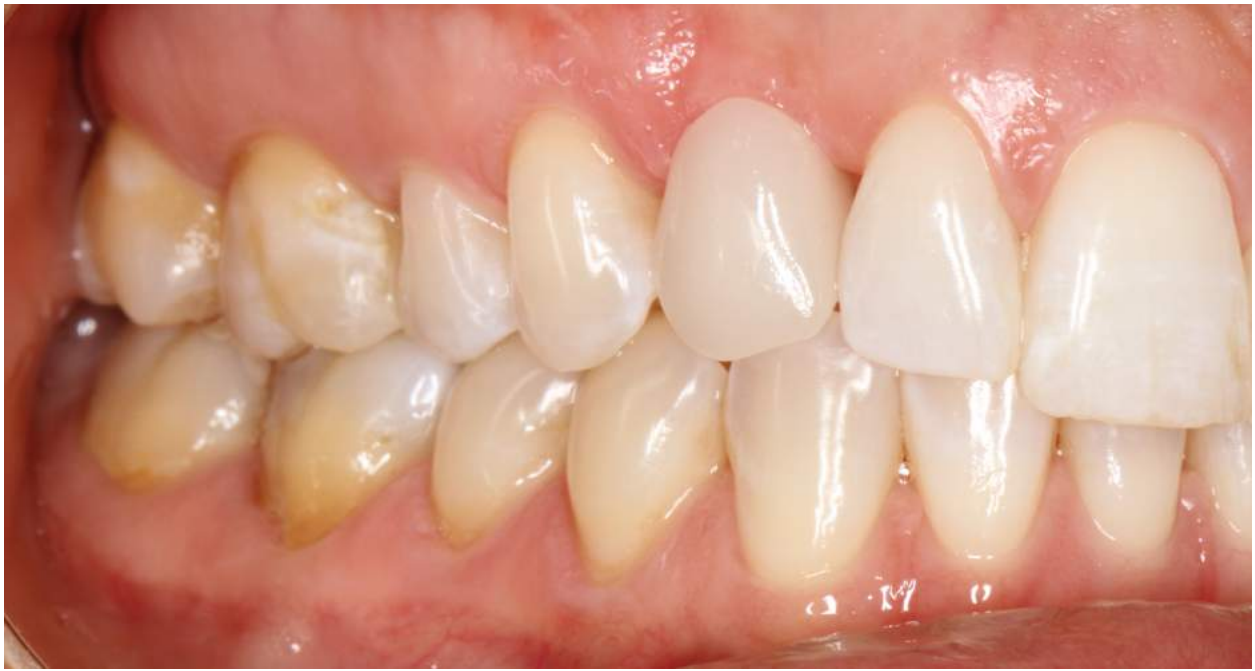
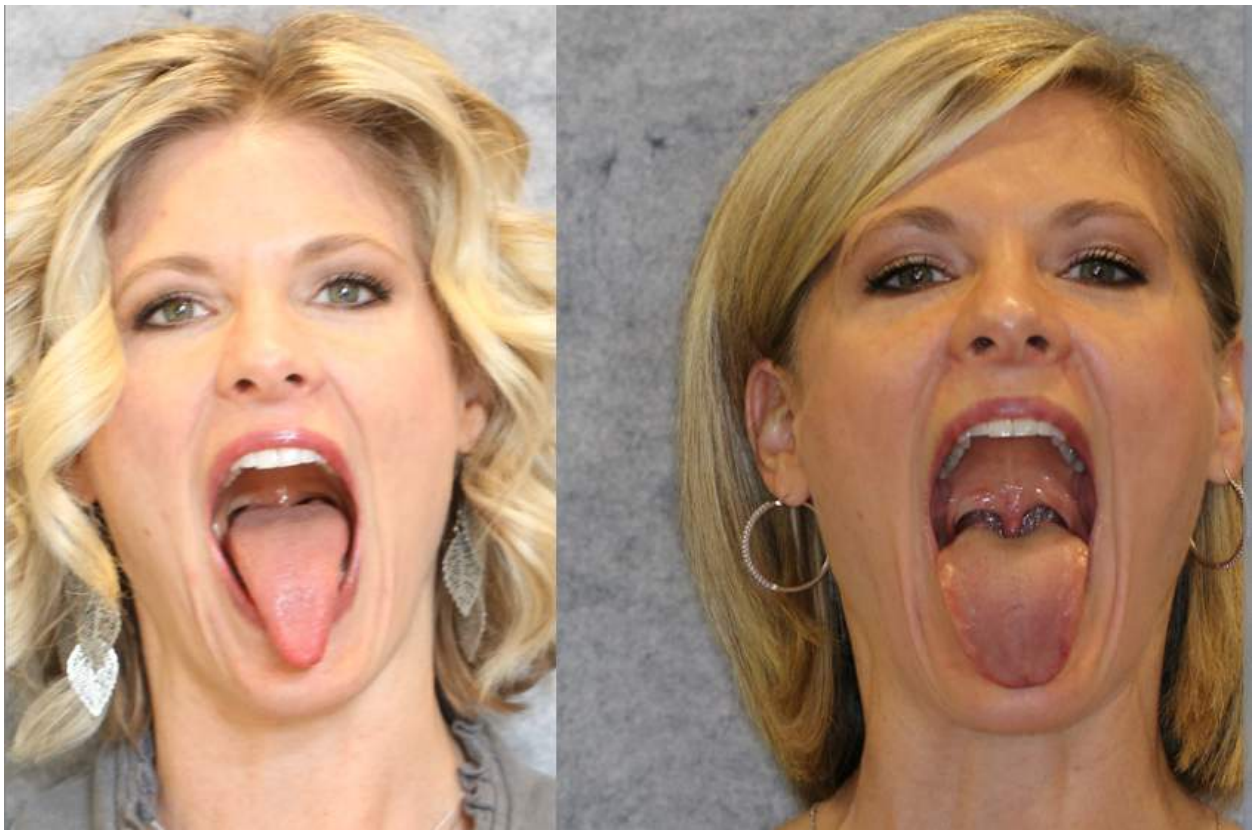
Fig. 4,5: 3 Shape Trios digital impression (upper image) and CeramillMind cad/cam design (lower image)





*Fig. 6: finished case, #6 eMax crown in vivo.*



*Fig. 7: patient's tongue after treatment, left and before treatment, right*