

Case Report: Splinted Restoration
On Two-Piece Zirconia Implants
Z-Systems Z5c, Tissue Level Implant



Dr. Jean Louis ROCHE
Implantologie Dentaire
Saint Laurent du Var - France
www.dr-roche.fr

The lower left first and second molars of a 54 years old female patient were replaced with two new two-piece ceramic implants and restored with splinted crowns. The implants (diameter: 4 mm, length: 10 mm) were placed 12 weeks after extraction (Nov. 23, 2012) with a classical flap elevation procedure without adjunct bone augmentation. Figure 1 and 2 show panoramic x-rays before and after implant surgery.

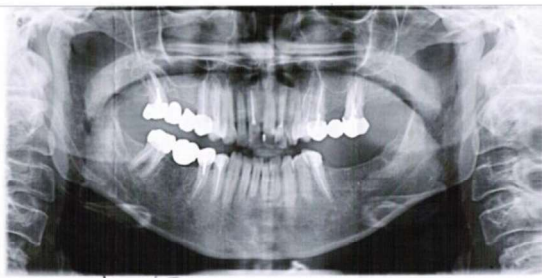


Fig. 1: panoramic x-ray before surgery

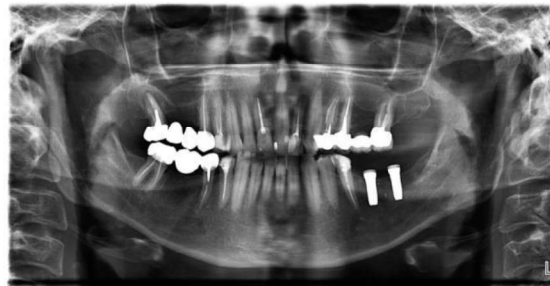

Fig. 2: panoramic x-ray after surgery

The clinical situation after primary wound closure can be seen in figure 3.

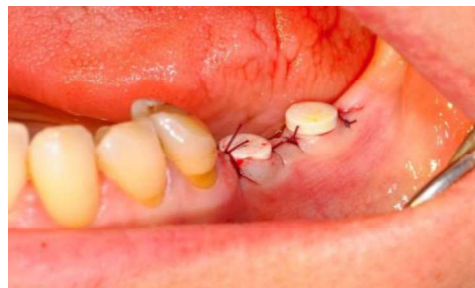

Fig. 3: clinical evaluation after suturing

The implants were allowed submucosal healing for 16 weeks (Mar. 3, 2013) before they were restored with straight abutments and splinted crowns in a second stage surgery (see figure 4).

The soft tissue's response around the zirconia implants is great, without any signs of inflammation. The height of the abutments had to be reduced (see figure 5) to let enough space for the future prosthetic restoration.

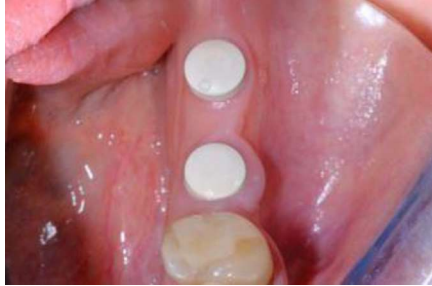

Fig. 4: clinical evaluation 16 weeks after surgery

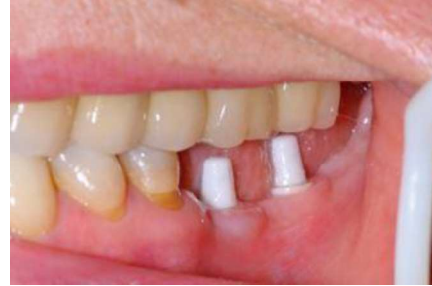

Fig. 5: abutment placement

After impression taking the patient was restored with two splinted ceramic crowns. Ten months later (Jan. 10, 2014), the patient was seen for a follow-up examination. Healing was uneventful and gingival health as well as crestal bone level maintenance are very good (see figures 6 and 7).

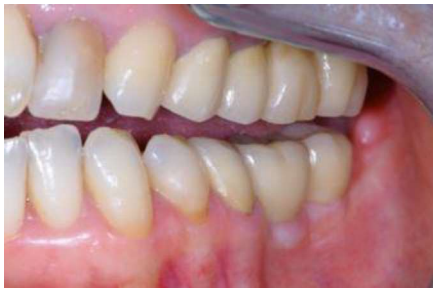

Fig. 6: clinical evaluation with final restoration in place

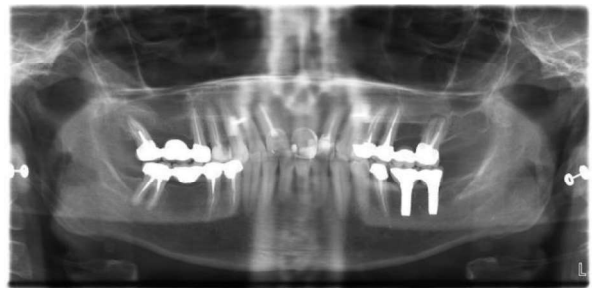


Fig. 7: x-ray follow-up after 10 months

Conclusion:

The new two-piece ceramic implant from Z-Systems shows excellent clinical results and crestal bone level maintenance. Z5c Tissue Level Implant is a reliable option for the prosthetic rehabilitation of missing molars.